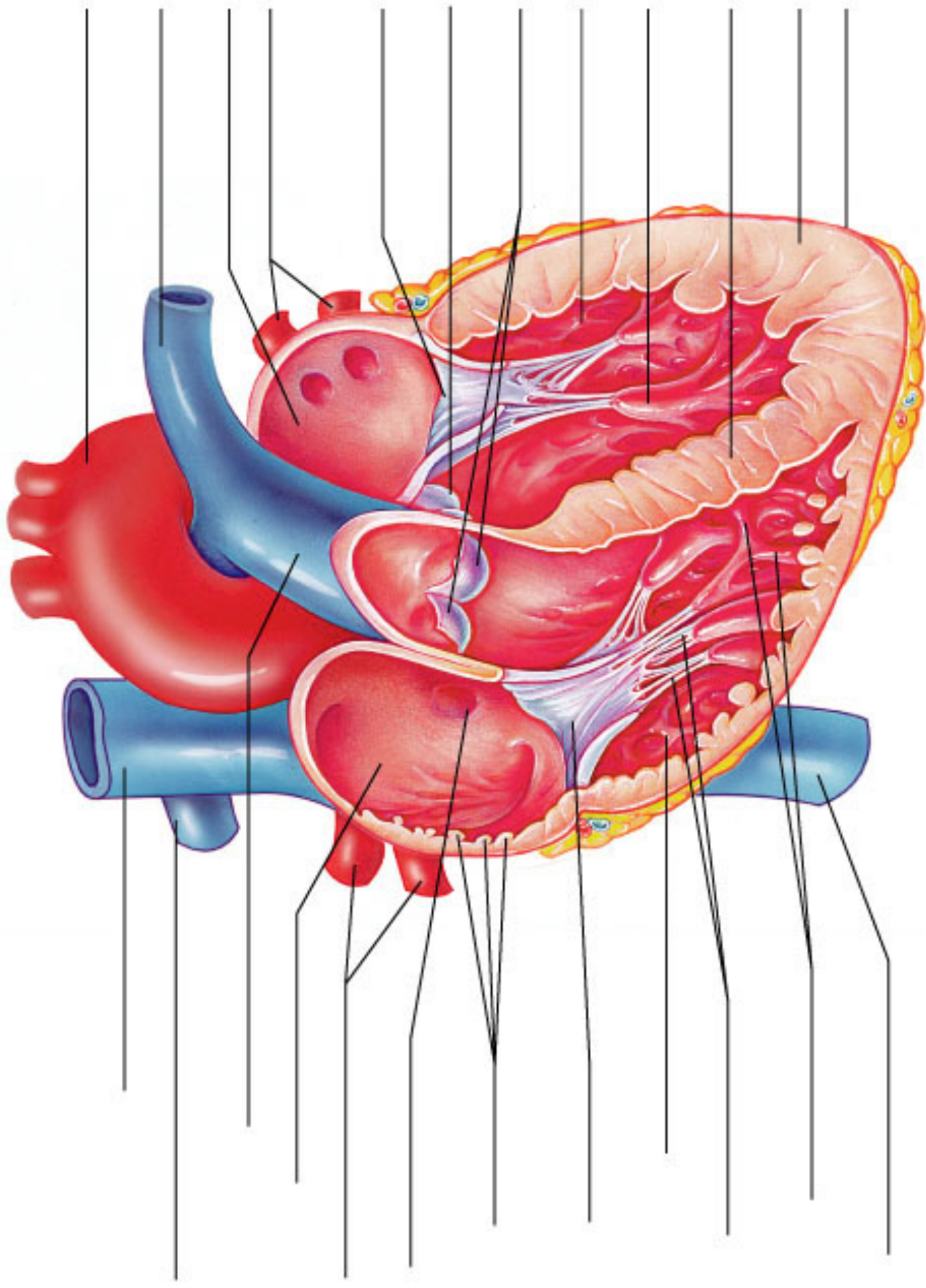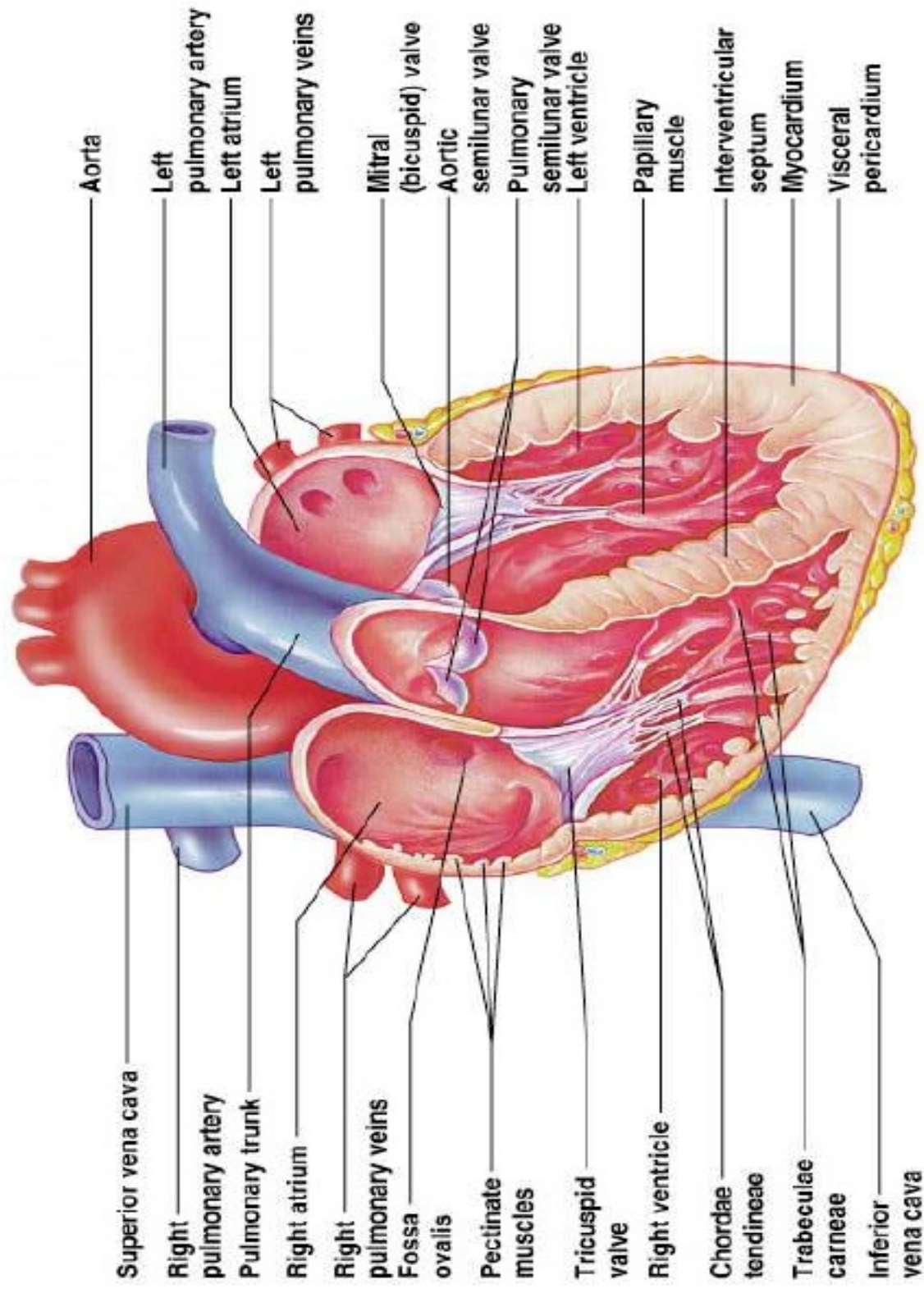
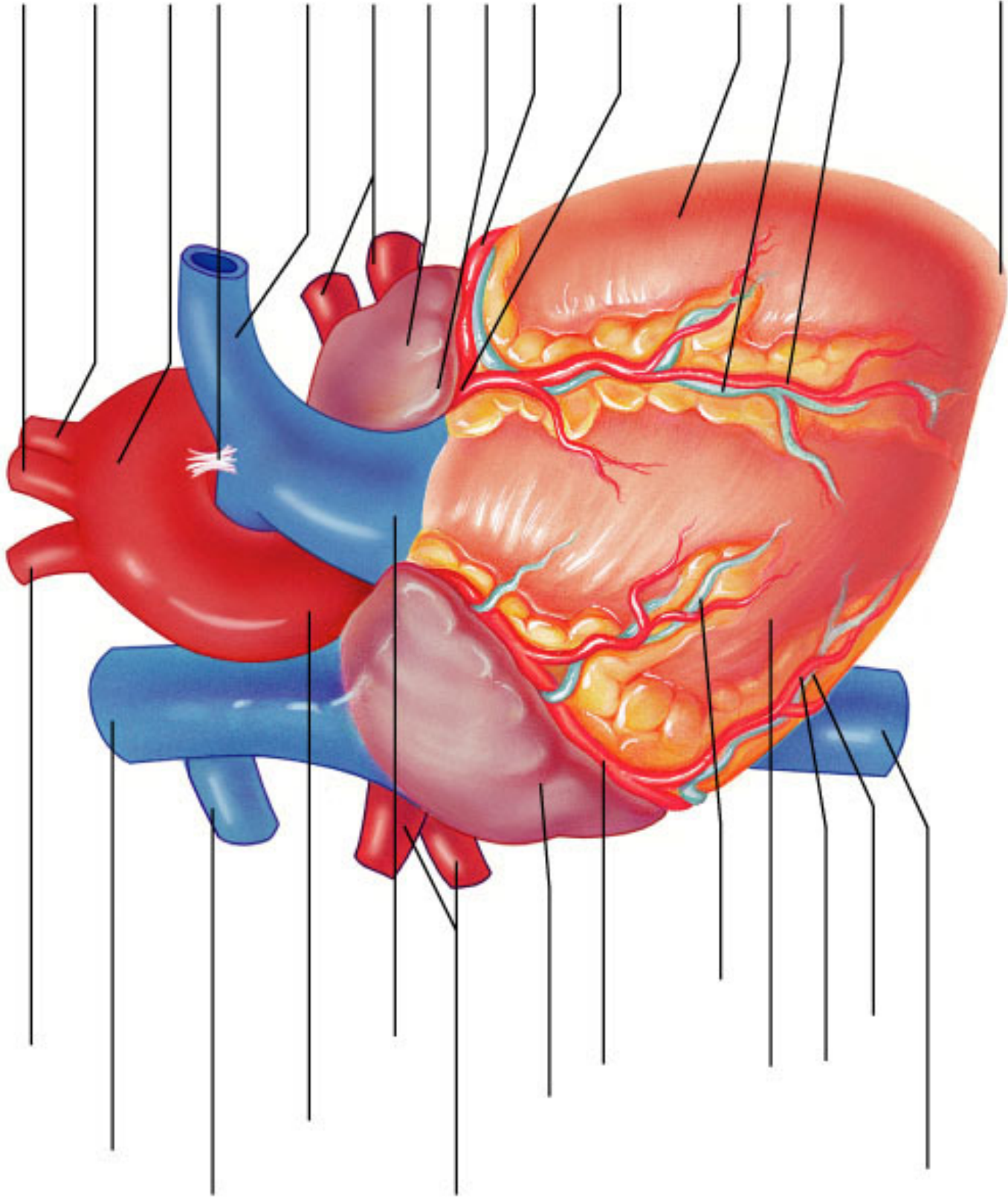


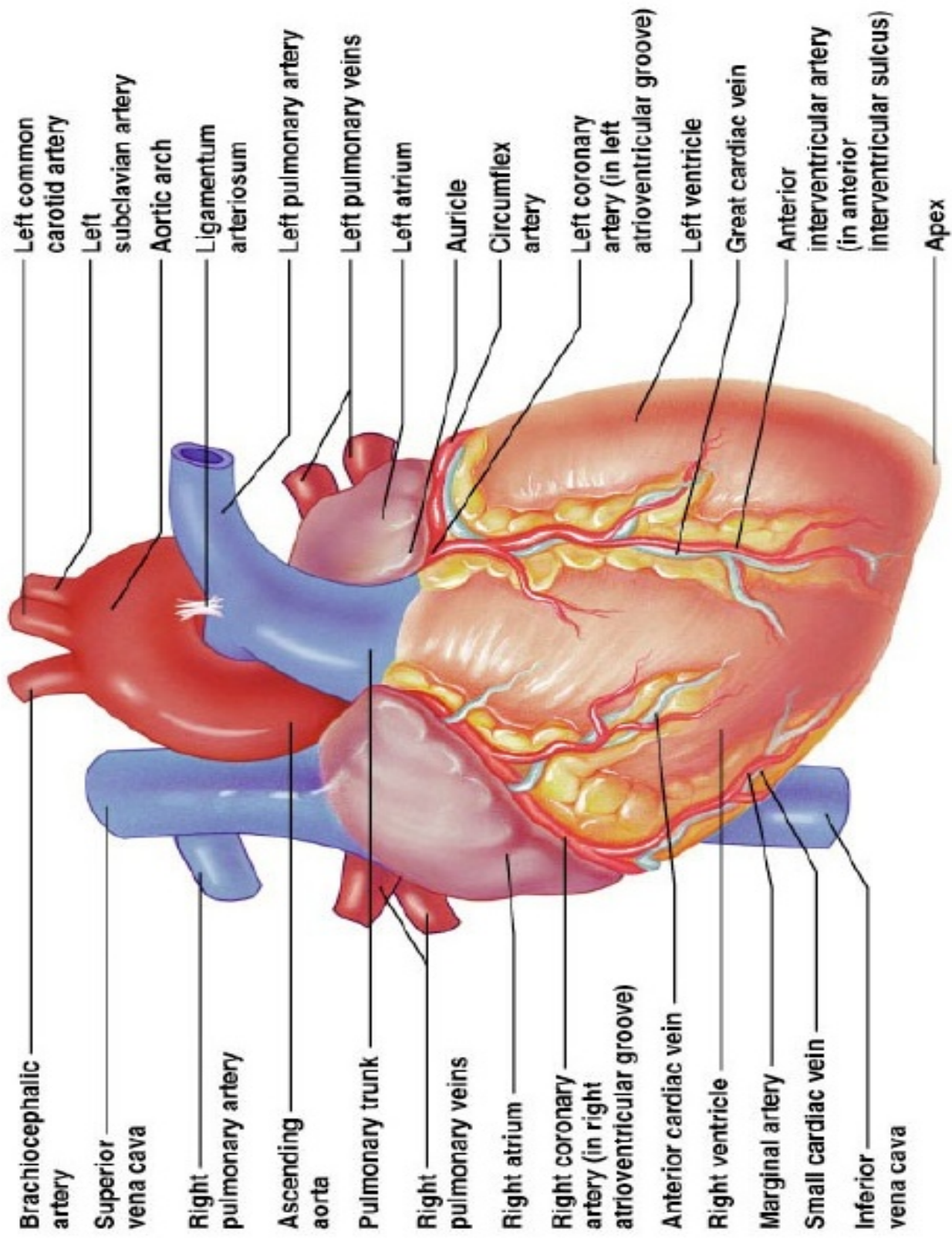
Internal, Frontal View



Internal, Frontal View



External, Anterior View



Brachiocephalic artery

Superior vena cava

Right pulmonary artery

Ascending aorta

Pulmonary trunk

Right pulmonary veins

Right atrium

Right coronary artery (in right atrioventricular groove)

Anterior cardiac vein

Right ventricle

Marginal artery

Small cardiac vein

Inferior vena cava

Left common carotid artery

Left subclavian artery

Aortic arch

Ligamentum arteriosum

Left pulmonary artery

Left pulmonary veins

Left atrium

Auricle

Circumflex artery

Left coronary artery (in left atrioventricular groove)

Left ventricle

Great cardiac vein

Anterior interventricular artery (in anterior interventricular sulcus)

Apex

External, Anterior View